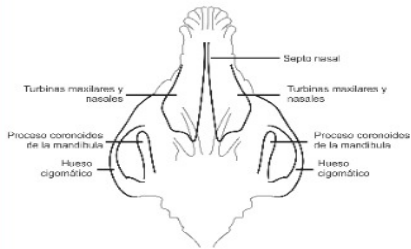
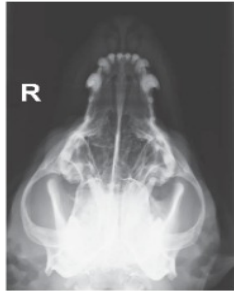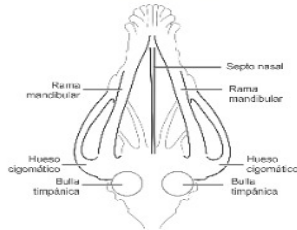

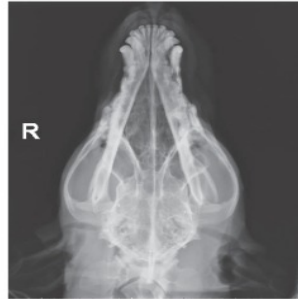
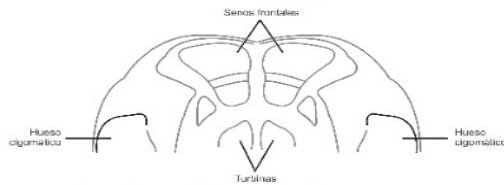
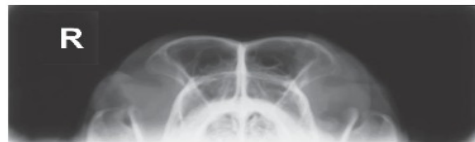
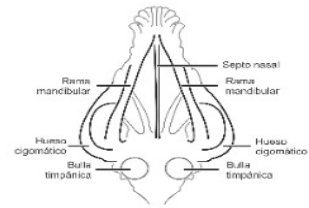
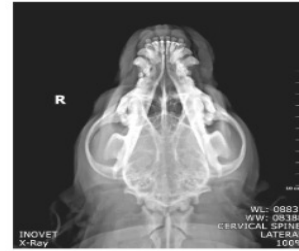VD Rostro Caudal con boca abierta



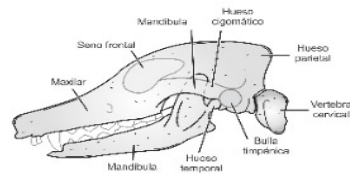
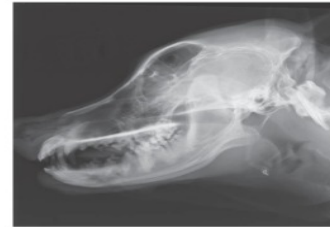DV de cráneo



VD de cráneo

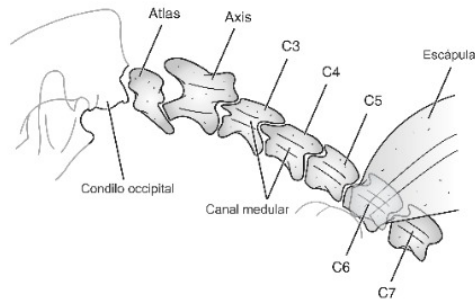
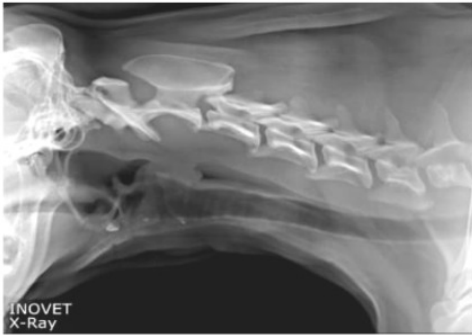

Rostro Caudal con boca cerrada

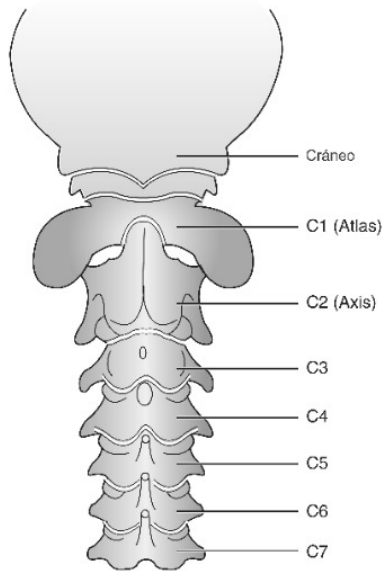
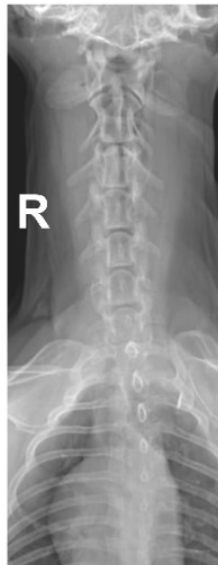

Lateral de cráneo

Lateral Cervical

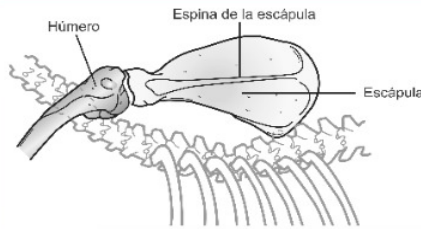
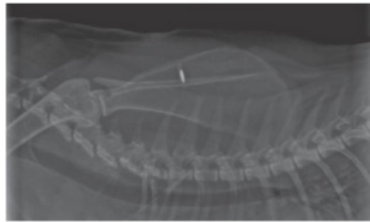

VD Cervical

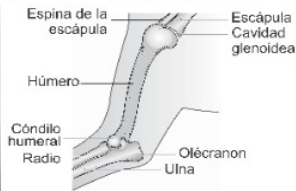
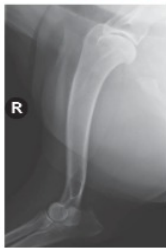

Esqueleto Apendicular (miembros anteriores)

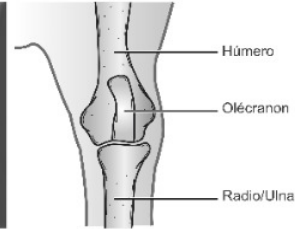
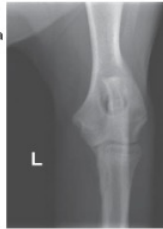Escápula



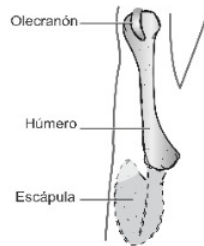
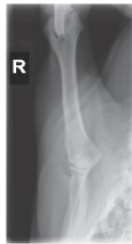ML Art. Hombro Codo



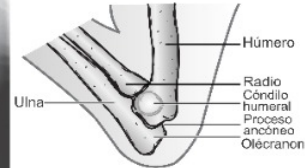
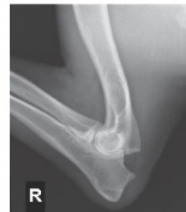AP Art. Codo



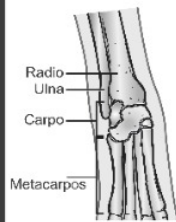
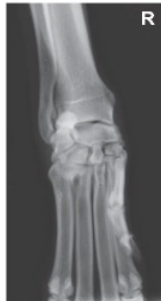PA Art. Hombro



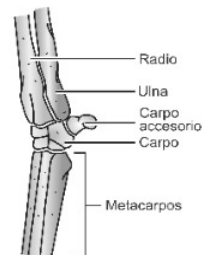
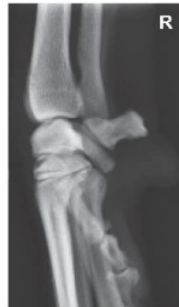ML en Hiperflexión Art. Codo



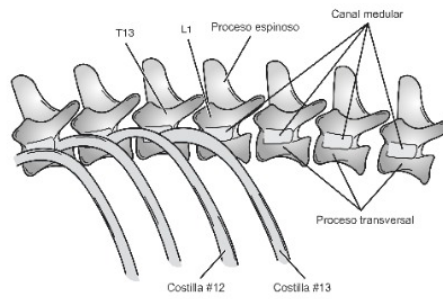
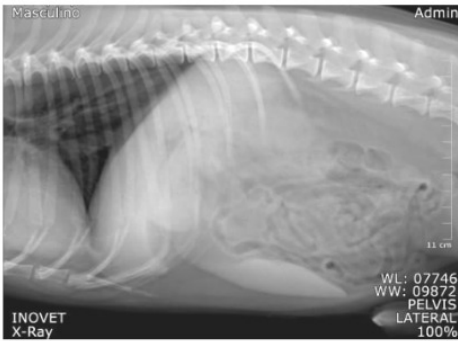
DP Art. Carpo



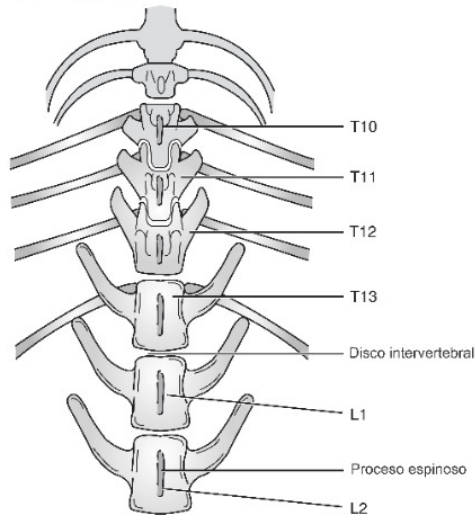
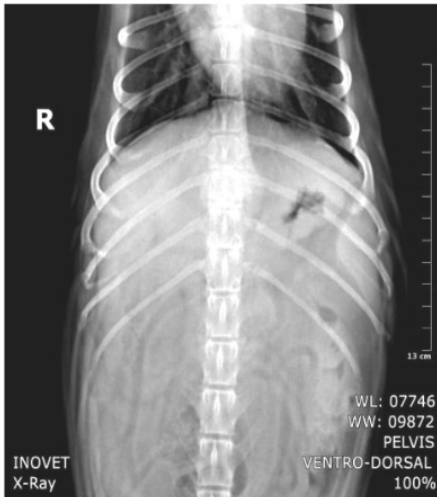ML Art. Carpo



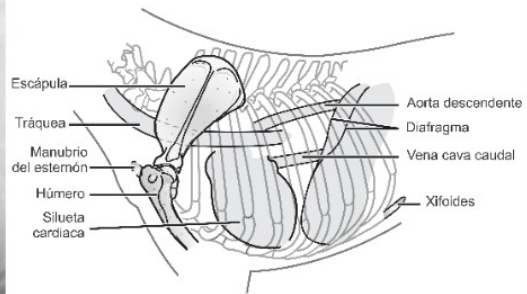
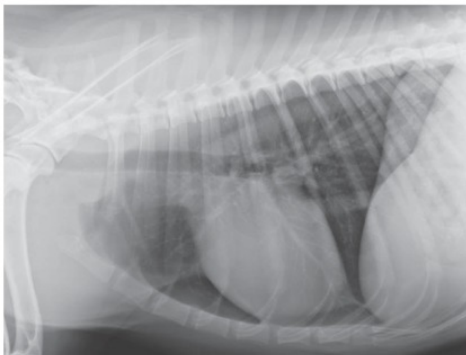
Lateral Toracolumbar



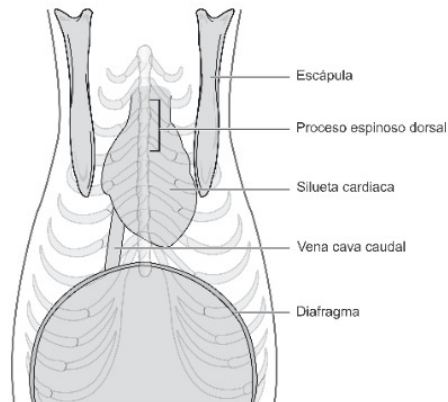
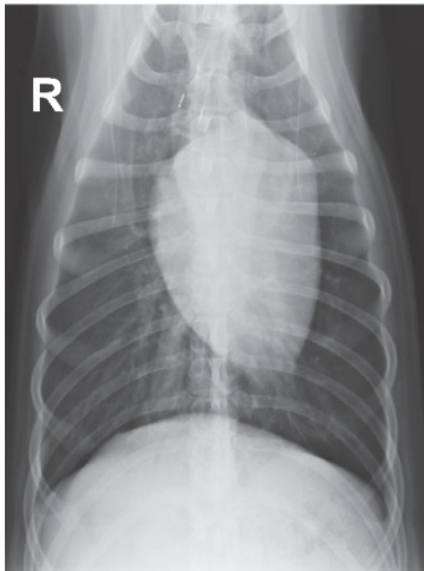
VD Toracolumbar



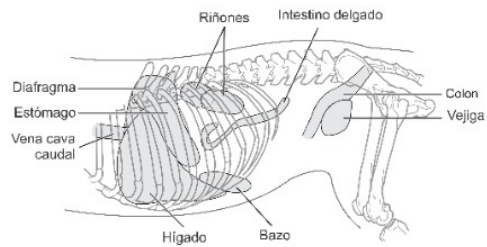
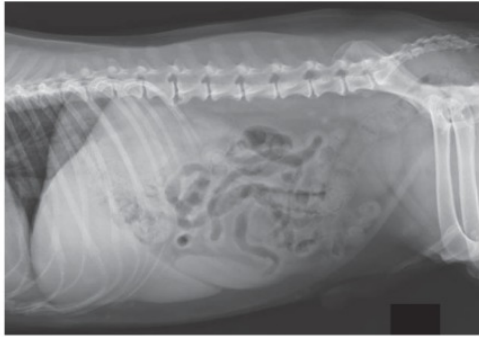Lateral Tórax



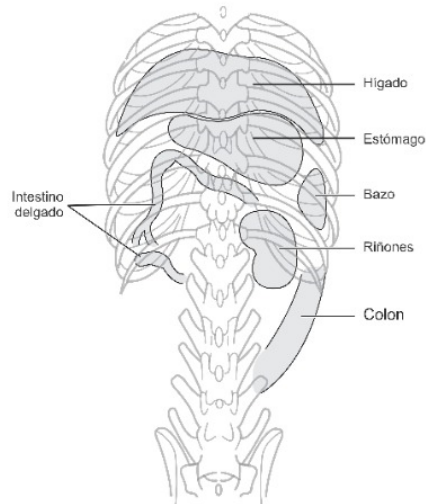
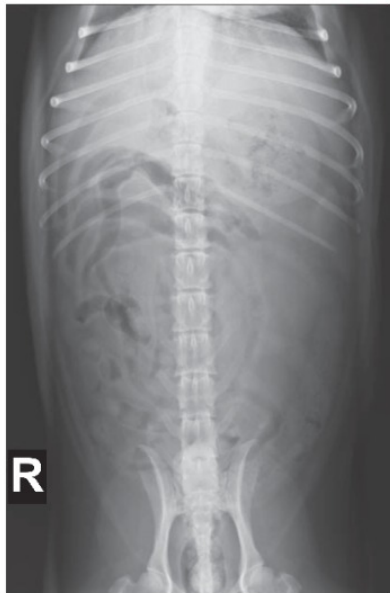VD Tórax



Lateral Abdomen



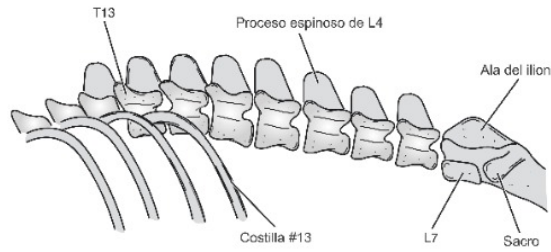
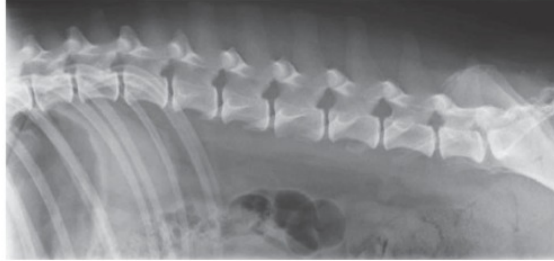
VD Abdomen



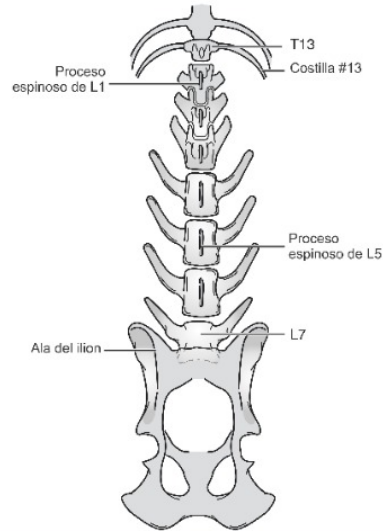
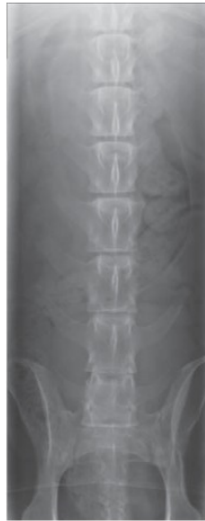

Editar con WPS Office

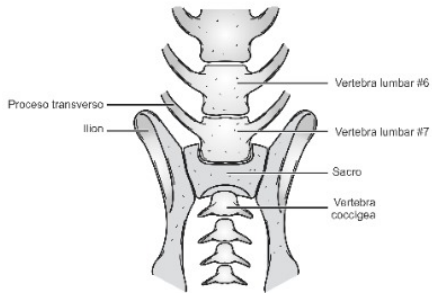
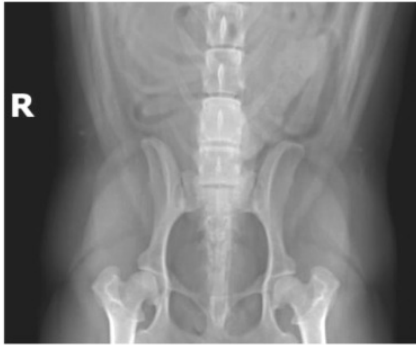
Lateral Lumbar



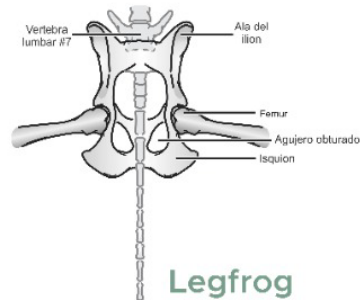
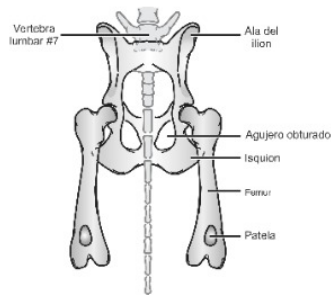
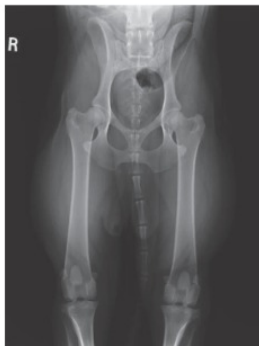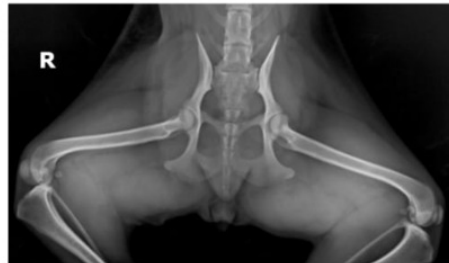
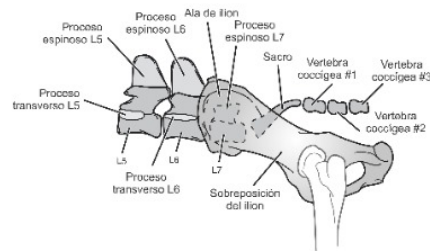
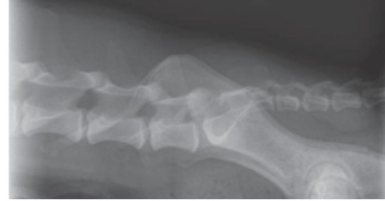VD Lumbar



VD Lumbosacra



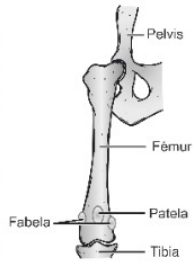
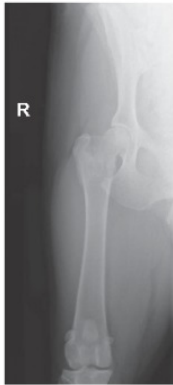Lateral Lumbosacra



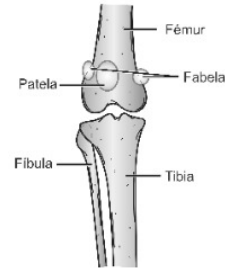
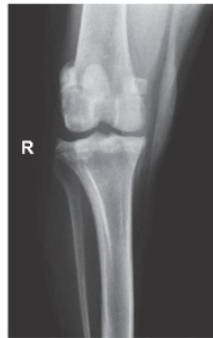VD de Pelvis

Legfrog

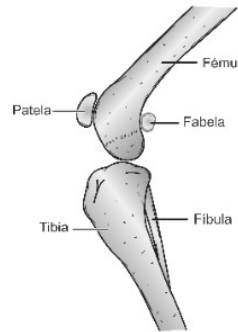
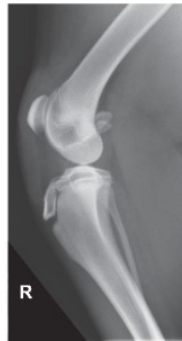AP de Fémur



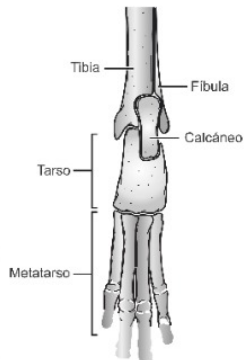
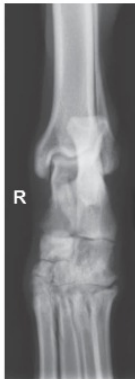AP de Rodilla



ML de Rodilla



AP de Tarso



ML de Tarso

